

CASE REPORT

Feedback-Modulated **Microcurrent** In Acupuncture Treatment

William P. Braun III, MD

ABSTRACT

Background Acupuncture point stimulation with both needles and transcutaneous **microcurrent** can be combined in the same treatment session. **Microcurrent** devices with feedback modulation characteristics offer theoretical advantages over those without them.

Objective To describe the outcomes of patients treated with acupuncture and transcutaneous feedback-modulated **microcurrent**.

Design, Setting, and Patients Four patients received treatment at a physician acupuncturist's practice. Two patients had chronic limb pain, 1 had acute migraine headache, and 1 had chronic depression.

Intervention A combination of acupuncture and acupuncture point stimulation with transcutaneous feedback-modulated **microcurrent**.

Main Outcome Measures Patient reports of pain level, activity level, and use of medication.

Results Chronic pain patients: 1 (disabled) patient had complete pain relief and returned to work, 1 experienced significant pain relief. The patient with acute headache had complete pain relief. The patient with depression was able to discontinue her medication.

Conclusions Acupuncture point stimulation with a combination of needles and transcutaneous feedback-modulated **microcurrent** can be used to satisfactorily treat a variety of conditions.

KEY WORDS

Acupuncture, **Microcurrent**, Feedback-Modulated **Microcurrent**, Pain

INTRODUCTION

Acupuncture points can be stimulated by a variety of means, including needles (with and without electrical stimulation), lasers, injections, pressure massage, magnets,¹ and colored light.² Points can also be stimulated by transcutaneous **microcurrent**, i.e., a current in the 1-999 mA range.

The use of **microcurrent** stimulation in acupuncture treatment is a logical development for several reasons. First, it has a profound effect on skin. Alvarez et al (3) demonstrated that **microcurrent** stimulation applied to wounds in pigs increased the rates of wound epithelialization and collagen synthesis.

Cheng et al showed that **microcurrent** stimulated amino acid uptake, and protein and ATP synthesis in rat skin tissue (4). Second, for more than two decades, **microcurrent** has shown promise in treating a variety of problems, including skin ulcers(5-7), nerve paralysis (8) periodontal disease, and trigeminal neuralgia (9). Third, Meyer and Nebrensky (10) state the therapeutic advantage of electrically stimulating skin sites of low electrical impedance; acupuncture points are known to be sites of lower electrical resistance (11).

Biedebach (12) has argued that treatment efficacy is determined by certain **microcurrent** waveform parameters. Research suggests that N-type voltage-sensitive calcium channels in cell membranes are more effectively opened by short electrical pulses(13). Other work suggests that L-type voltage-sensitive calcium channels are more effectively opened by longer pulses (14). N-type channels tend to predominate on sensory neurons and stimulate the release of powerful vasodilating substances such as calcitonin gene-related peptide, whereas L-type channels predominate on fibroblasts (15). Theoretically, it would be advantageous for a **microcurrent** device to incorporate both characteristics into its waveform, and to adjust each component in response to changing tissue electrical impedance in an attempt to optimize the effect.



Figure 1. Electro-Acuscope Model 80C (circa 1991)

One **microcurrent** device (Figure 1) addresses this issue (16). The current waveform (Figure 2) has an "overshoot" phase, which acts as a short-duration pulse to open N-type channels, and a longer duration "plateau" phase to open L-type channels. In 1 model, the current overshoot is maintained between 1.5 and 2.0 mA. The width of the overshoot (measured at the 1.0-mA level) is automatically adjusted between 100 and 300 microseconds by a feedback mechanism in response to the measured tissue impedance. The width of the overshoot increases with decreasing tissue impedance; this is believed to open more N-type channels. The plateau phase width is automatically adjusted between 2 and 200 milliseconds commensurate with tissue impedance in an attempt to optimize the opening of L-type channels. The amplitude of the plateau phase is determined predominantly by the manually adjusted intensity dial on the outside of the device. A train of positive-going "carrier pulses" is followed by a train of negative-going carrier pulses to complete a 4-second repeating cycle

(Figure 3). The carrier pulse frequency is adjusted manually by the frequency dial. Treatment is rendered by use of attachable electrodes including (but not limited to) brass "mini plates," "point-specific probes" with brass tips, "transcranial clip" (earclip) electrodes, and an "auricular probe" with a thin, spring-loaded, stainless steel tip for the detection and treatment of auricular points (Figure 4).

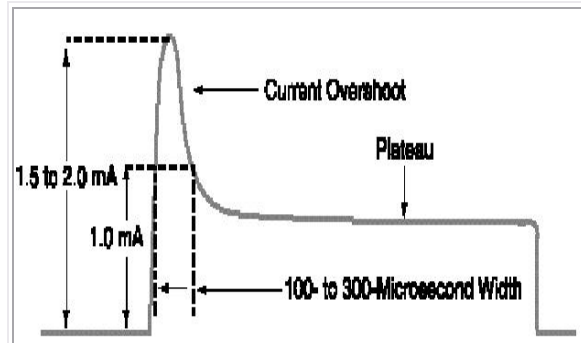


Figure 2. Current Waveform (single pulse — current vs time)

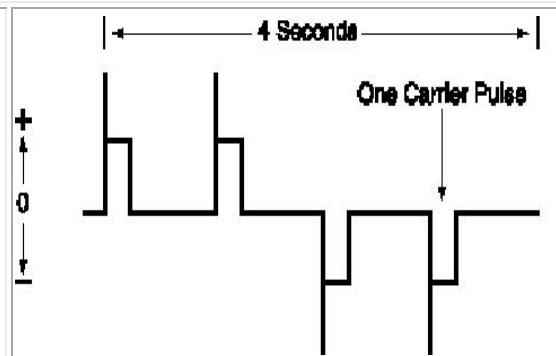


Figure 3. Waveform Repeating Cycle (at 1 Hz — current vs time)

CASE REPORTS

Patient 1

History and Physical Findings

A 52-year-old man presented with a 7-year history of pain, swelling, and varicosities in his left leg, and an inability to work as a forklift operator. He had sustained a severe work-related injury to his left knee, subsequently developing a stasis problem. Surgery 1 month prior to presentation produced temporary relief, but his condition completely relapsed. The patient reported "shooting pains" in his heel and calf even at rest, worse with ambulation, and with no significant relief from medication.

Physicians at a regional occupational medicine practice advised him that no further surgery or treatment was warranted. The patient had no other active medical problems. On physical examination, marked varicosities and 2+ non-pitting edema were noted at the left leg, ankle, and foot, as well as multiple surgical scars. His calf was so tender that he could not rest it on the examining table, and kept his knee and hip flexed. He ambulated with a limp.

Diagnosis

Pain and severe venous stasis in the left leg.

Treatment

The patient was initially treated 3 times at weekly intervals. Treatment included acupuncture with 32-gauge needles at points SP 6, LU 7, and ST 40, bilaterally, with electrical stimulation using an electroacupuncture stimulator at 2.5 Hz between SP 6 (-) and LU 7 (+) for 20 minutes. Treatment also included transcutaneous electrical nerve stimulation for 10 minutes at 300-500 mA, 0.5 Hz, with a

1" mini-plate electrode at left SP 6, and a 2" mini-plate electrode centered at left SP 12.

Results

After the 1st treatment session, the patient noted that his leg pain had largely resolved and the swelling had significantly decreased. At the beginning of the 3rd visit, the patient reported no pain and his limp had resolved. Shortly thereafter, he returned to his job, working 10-hour days.

Approximately 11/2 months later, the patient reported ankle and foot pain. He was treated 2 more times as delineated above, one week apart, with complete resolution of pain, missing only one day of work. Subsequently, four 1/2 months after the first treatment, he was doing very well.

Patient 2

History and Physical Findings

A 64-year-old woman presented with a history of longstanding depression, treated with imipramine hydrochloride for 2 decades, up to 150 mg/d. All attempts to wean her from medication had failed since return of severe symptoms required resumption of the medication. Otherwise, she was healthy with an unremarkable medical history except for a strong family history of depression. Findings of the physical examination were unremarkable.

Diagnosis

Major depression.

Treatment

Initially, imipramine was continued at 75 mg/d. The patient was treated weekly with acupuncture, sometimes biweekly, for nearly 3 months, using mostly a modification of the "Internal Dragons" protocol (ST 32, 36, 41, tender point between CV 14 and CV 15; 32-gauge needles for 20 minutes). Moreover, during this period, she was treated with **microcurrent** stimulation using the auricular probe at right ear points including Stomach, Cerebellum, Mouth, Shen Men, Zero Point, Master Cerebral Point, Master Oscillation Point, Cheerfulness Point, Excitement Point, and Triple Heater (24 seconds per point, 25 mA, 2.5 Hz, ground electrode at the right hand).

Results

Treatment continued as delineated above; the patient was slowly weaned from imipramine in 10-15 mg increments, biweekly. The medication was discontinued within 2 months. Toward the end of this period, the patient experienced some insomnia, which improved after adding the following ear points: Sleep Disorder 1 and 2, and Heart points. Subsequently, the above protocol was discontinued. The patient was treated at 2-4 week intervals, 50 minutes per session, using cranial electrotherapy stimulation (**microcurrent** brain stimulation via earclip electrodes) with **microcurrent** stimulation at 0.5 Hz, 100 mA. Her condition has remained stable for more than 8 years.

Patient 3

History and Physical Findings

A 37-year-old woman with a personal and family history of migraine headaches

presented with an acute common migraine headache, reporting pain in the left frontal and temporal areas (no medication had been ingested that day). The patient was generally in good health, and the physical examination findings were unremarkable except for facial expression indicating pain, and tenderness at left GB 21.

Diagnosis

Acute migraine headache.

Treatment

The patient was treated on 1 occasion with the **microcurrent** device using two point probes, one on left GB 1, the other on left GB 21 (200 mA, 0.5 Hz, 5 minutes). Also, acupuncture needles were inserted into the left ear points, forehead, and temples, and removed in 20 minutes.

Results

Within 20 minutes after the onset of treatment, the patient reported complete pain relief; she remained headache-free at follow-up 12 days later.





Figure 4.
Electrodes: Mini Plates (1", 2", 1x3"), Point-Specific Probe, Transcranial Clip (Ear Clip), Auricular Probe

Patient 4

History and Physical Findings

A 55-year-old man presented with a 10-year history of right shoulder pain. The patient reported falling onto his right shoulder 20 years previously. He reported pain when reaching forward, reclining on his right shoulder, and on using a work-related machine. He had been treated with cortisone injections intermittently in both shoulders; recently, pain had not subsided. Aspirin, acetaminophen, or naproxen was used for pain.

The physical examination showed some atrophy of the musculature in the right upper trapezius distribution, near normal range of motion of the neck, and mildly restricted passive range of motion at the right shoulder. Also, motor strength was 4/5 for internal and external rotation at the right shoulder, limited by pain, with 5/5 strength on the left.

Diagnosis

Right shoulder bursitis.

Treatment

The patient was treated 3 times at weekly intervals. All 3 visits involved acupuncture with 32-gauge needles using the French Energetics "Contrary and Inverse" approach (right LI 10, 15, 16, 18, left KI 10, LI 15, ST 36 for 20 minutes). **Microcurrent** stimulation with auricular probe was performed on the right ear at the first 2 visits (Shen Men, Shoulder, Master Shoulder, Thalamus; 25 mA, 2.5 Hz, 24 seconds per point, ground electrode placed in right hand). On the last 2 visits, he was also treated with the same device with a 1" mini-plate electrode at right LI 15, and a point-specific probe first at right LI 10 (5 minutes), and then at right LI 16 (5 minutes, 200 mA, 0.5 Hz).

Results

At the 3rd visit, the patient reported considerable improvement; he reported no work-related pain. His passive range of motion at the right shoulder was normal, and he had a modest increase in right shoulder range of motion; internal/external rotation strength improved to 5/5. Four months later, he did not report any deterioration in his condition.

DISCUSSION

These case reports represent a small sample of the author's 10-year experience treating patients with acupuncture and **microcurrent** stimulation. It is not possible to measure the separate contributions of each modality based on these reports; however, the two combined techniques tend to produce results superior to either alone, especially for pain problems. Also, comparisons of the efficacy of **microcurrent** devices with this particular feedback mechanism vs those without

it have not been performed.

Regarding Case 1, Spleen meridian points were chosen for both the acupuncture and **microcurrent** portions because this meridian is indicated for edema; ST 40 was added to the acupuncture portion because this point is specifically indicated for lower extremity edema.¹⁷ The **microcurrent** frequency, current intensity, and duration were based on the author's experience. The electroacupuncture frequency at 1-4 Hz is useful for chronic conditions in general.

In Case 2, the ear points were chosen based on suggestions in an auriculotherapy manual.¹⁸ The choice of the 2.5-Hz frequency for all auricular points was a compromise. (This particular **microcurrent** device model lacks a 5-Hz setting; 2.5 Hz is a lower frequency harmonic of all the other ear region-specific frequencies in that manual.) The duration of auricular point stimulation was based on protocols available from the device distributor.¹⁶ Auricular therapy was performed on 1 ear only. With respect to cranial electrotherapy stimulation, a brief review is available elsewhere.¹⁹ Finally, the modified "Internal Dragons" protocol has been recommended for the treatment of depression in the UCLA acupuncture course lectures.²⁰

Case 3 is an example of trigger point treatment with **microcurrent**. In the author's experience, placing 1 electrode on an acupuncture point at or near a trigger point, and the other electrode on an acupuncture point within the region of referred pain, can be extremely effective, especially when both points are on the same meridian.

In Case 4, 4 points were chosen along the LI meridian located in the shoulder region for **microcurrent** treatment; in the author's experience, this is useful for shoulder pain in general. The auricular points were treated on the right ear only as they were not well detected on the left ear. The "Contrary and Inverse" French Energetics technique was chosen for the acupuncture portion because of its usefulness in treating limb pain.²⁰

CONCLUSION

My observations tend to indicate that acupuncture point stimulation with a combination of transcutaneous stimulation, feedback-modulated **microcurrent**, and needles can be effective. Studies involving feedback-modulated vs non-feedback-modulated **microcurrent** and acupuncture treatment with and without **microcurrent** stimulation remain a research challenge.

REFERENCES

1. Yamamoto T, Yamamoto H. Yamamoto New Scalp Acupuncture (YNSA). Tokyo, Japan: Axel Springer Japan Publishing Co; 1998:93-94.
2. Mandel P. Practical Compendium of Colorpuncture. Bruchsal, Germany: Energetik Verlag; 1986.
3. Alvarez OM, Mertz PM, Smerbeck RV, Eaglstein WH. The healing of superficial skin wounds is stimulated by external electrical current. *J Invest Dermatol.* 1983;81:144-148.
4. Cheng N, Van Hoof H, Bockx E, et al. The effects of electric currents on ATP generation, protein synthesis and membrane transport of rat skin. *Clin Orthop.* 1982;171:264-272.
5. Assimacopoulos D. Low intensity negative electric current in the treatment of ulcers of the leg due to chronic venous insufficiency: preliminary report of three cases. *Am J Surg.* 1968;115:683-687.
6. Gault WR, Gateus PF Jr. Use of low intensity direct current in management of ischemic skin ulcers. *Phys Ther.* 1976;56:265-269.
7. Wood JM, Evans PE 3d, Schallreuter KU, et al. A multicenter study on the use of pulsed low-intensity direct current for healing chronic stage II and stage III decubitus ulcers. *Arch Dermatol.* 1993;129:999-1009.
8. Stefanatos J. Treatment to reduce radial nerve paralysis. *Vet Med Small Animal Clin.* 1984;79:67-70.
9. Stellabotte RJ. Control of pain with the Electro-Acuscope. *American Endodontic Society Newsletter.* 1988; No. 54.
10. Meyer FP, Nebrensky A. A double-blind comparative study of the Electro-Acuscope and placebo effect in short term treatment of the chronic back pain patient. *California Health Rev.* 1983;2.
11. Hyvarinen J, Karlsson M. Low-resistance skin points that may coincide with acupuncture loci. *Med Biol.* 1977;55:88-94.
12. Biedebach MC. Accelerated healing of skin ulcers by electrical stimulation and the intracellular physiological mechanisms involved. *Acupunct Electrother Res.* 1989;14:43-60.
13. Miller RN. Multiple calcium channels and neuronal function. *Science.* 1987;235:46-52.
14. Nowycky MC, Fox AP, Tsien RW. Long-opening mode of gating of neuronal calcium channels and its promotion by the dihydropyridine calcium agonist Bay K 8644. *Proc Natl Acad Sci U S A.* 1985;82:2178-2182.
15. Fox AP, Nowycky MC, Tsien RW. Kinetic and pharmacological properties distinguishing three types of calcium channels in chick sensory neurones. *J Physiol (Lond).* 1987;349:149-172.
16. Pacific Biomedical Systems International. Huntington Beach, Calif.
17. O'Connor J, Bensky D, trans. *Acupuncture: A Comprehensive Text* (Shanghai College of Traditional Medicine). Seattle, Wash: Eastland Press; 1981:51, 273.
18. Oleson T. *Auriculotherapy Manual: Chinese and Western Systems of Ear*

- Acupuncture. Los Angeles, Calif: Health Care Alternatives; 1990.
19. Kirsch D, Lerner F. Electromedicine: the other side of physiology. In: Weiner R, ed. Pain Management: A Practical Guide for Clinicians. Boca Raton, Fla: CRC Press; 1998:842-846.
 20. Helms J. Acupuncture Energetics: A Clinical Approach for Physicians. Berkeley, Calif: Medical Acupuncture Publishers; 1995:614-619.

AUTHOR INFORMATION

Dr William P. Braun III is a Board-certified Family Practitioner and registered acupuncturist at the Geisinger Health System/White Haven-Blakeslee Clinic in White Haven, Pennsylvania.

William P. Braun III, MD
Geisinger Medical Group
HCR 1, Box 22G
White Haven, PA 18661
Phone: 570-443-9559 o Fax: 570-443-7024
E-mail: wbraun@geisinger.edu

Editor's Note: The acupuncture physician is confronted with many different types of equipment on the market to select for patient care. It is important that we note which devices are not clinically suitable and avoid negative clinical outcomes. The term, impedance, is used with alternating currents denoting capacitance and inductive components. The term, resistance, is more correctly used with direct current. The acupuncture point has resistance measured in ohms if the flow of current through the point has a frequency of 0 Hz. Likewise, a current of 10 Hz, for example, through an acupuncture point, has an impedance measured in ohms. Unfortunately, the terms "impedance" and "resistance" are often used interchangeably, and may not be correct, depending on the electrical circumstances.